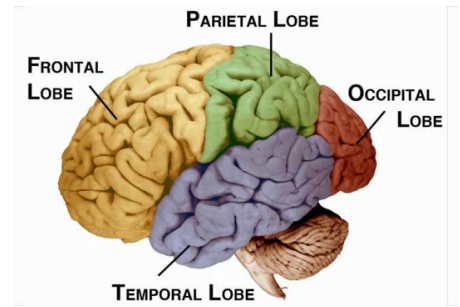


TOPOGRAPHY OF THE BRAIN

THE CORTEX

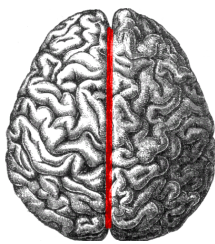
The cortex is generally the phylogenetically newest area of the brain. On an anatomical level it consists of four lobes, separated by key landmarks. On a functional level it can be divided into three main categories:

- **Primary areas** – are clearly linked to certain body parts providing direct sensory or motor function
- **Association areas** – have broader less specific motor or sensory function
- **Limbic areas** – a mix of interlinking areas with a variety of functions from emotion to long term memory storage



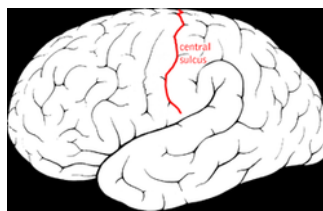
The highly folded surface of the cerebral cortex forms **gyri** (ridges) and **sulci** (valleys). It is divided by a few main sulci:

LONGITUDINAL FISSURE



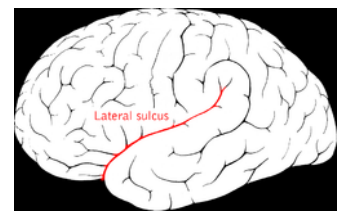
Separates the two **cerebral hemispheres**. The hemispheres are still connected by a collection of fibres known as the corpus callosum

CENTRAL SULCUS



Separates the **primary motor cortex** anteriorly from the **primary sensory cortex** posteriorly

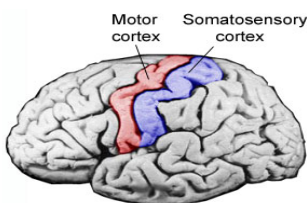
LATERAL FISSURE



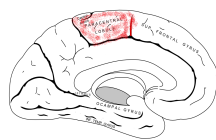
Separates the temporal lobe from the parietal and frontal lobes

Some gyri are very well defined and can be identified on specimens. Others like the association areas can be roughly demarcated and are more difficult to precisely identify

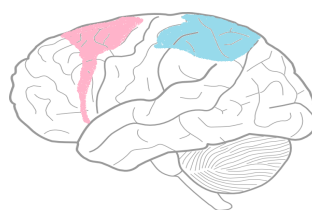
PRIMARY MOTOR CORTEX & PRIMARY SENSORY CORTEX



Primary areas for sensory and motor input. The section of the primary motor and sensory cortex on the medial aspect of the cerebral cortex is called the Paracentral lobule (right)

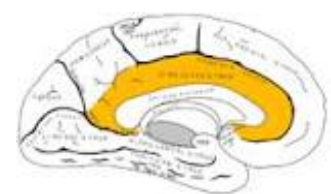


MOTOR AND SENSORY ASSOCIATION AREAS



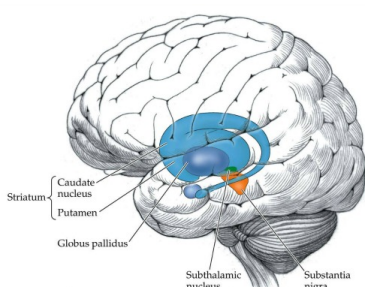
Intergrate and translate the complex sensory input from the primary sensory and motor cortices to build a meaningful understanding of the world

CINGULATE GYRUS




Part of the limbic system, located above the Corpus callosum

BELOW THE CORTEX



The basal nuclei (sometimes called ganglia) are a collection of subcortical nuclei. These 'centres' of information have connections all over the brain and are associated with many functions from movement to emotions.

➤ Check out this *soton brainhub* video on the basal nuclei and their role in Parkinson's disease!



MENINGES

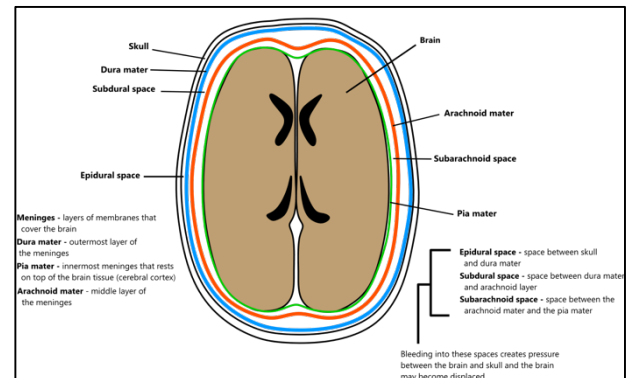
WHAT ARE THE MENINGES?

The meninges are three layers of connective tissue that surround the brain and spinal cord. The innermost layer is the **pia mater**. This closely envelops the central nervous system (CNS: Brain + Spinal Cord), and enters each sulci of the brain. Superficial to the pia mater is the **arachnoid mater**. This is a thin layer that does not enter the sulci. Superficial to the arachnoid mater is a tough fibrous layer called the **dura mater**. The dura consists of two layers: an outer **endosteal** layer and an inner **meningeal** layer.

SPACES

Between the layer of the meninges there are spaces: some are real spaces, others are 'potential spaces' that only exist in the presence of pathology.

- **Epidural:** A real space between the dura and overlying bone. In the spine, medication can be injected here for anaesthesia, for example during labour.
- **Subdural:** A potential space between the dura and arachnoid mater.
- **Subarachnoid:** A real space between the arachnoid mater and pia mater. The main arterial supply to the brain, the *Circle of Willis* lies within this space.

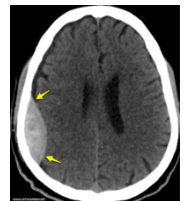


CLINICAL LINK: BLEEDS

There are three main bleeds associated with the meninges: **extradural haematoma** and **subdural haematoma**, and **subarachnoid haemorrhage**.

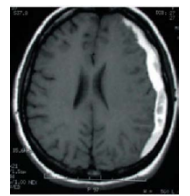
EXTRADURAL HAEMATOMA

- Usually damage to the **Middle Meningeal Artery** over the *pterion*. Presents shortly after injury with diminished consciousness.



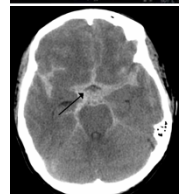SUBDURAL HAEMATOMA

- Caused by tearing of some of the many **bridging veins** which penetrate into the *Superior Sagittal Sinus*. This usually presents a few hours after the injury with diminished levels of consciousness.



SUBARACHNOID HAEMORRHAGE

- Usually caused by rupture of aneurysm of the *Circle of Willis*, characterised by a **Thunderclap headache** and loss of consciousness. Although rare, this is the most common type of haemorrhagic stroke.



KEY TERMS

- Pia Mater
- Arachnoid Mater
- Dura Mater: Endosteal and Meningeal Layers
- Epidural Space
- Subdural Space
- Subarachnoid Space
- Extradural Haematoma
- Middle Meningeal Artery
- Subdural Haematoma
- Bridging Veins
- Subarachnoid Haemorrhage
- Thunderclap Headache

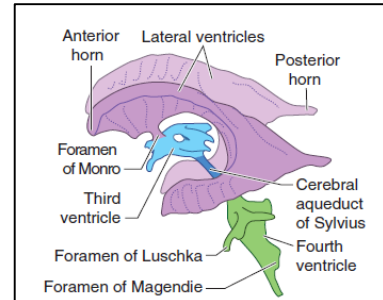
VENTRICLES

FLOW OF CSF

Within the brain, there are a series of spaces collectively called the **ventricular system**. This is where **cerebrospinal fluid** (CSF) is produced and flows. You can see these on imaging and within the specimens. The ventricular system is comprised of:

- Two **Lateral Ventricles**
- One **Third Ventricle**
- One **Fourth Ventricle**

Each ventricle is connected to one another by a small hole, a **foramen**, or a longer narrow structure.



Between each lateral ventricle and the singular third ventricle is the **Foramen of Munro**. Between the third ventricle and fourth ventricle is the **Cerebral Aqueduct**. From the fourth ventricle, CSF passes into the subarachnoid space through three foramina: a singular foramen in the midline called **Foramen of Magendie**, and two lateral foramina called the **Foramen of Luschka**. CSF flows around the subarachnoid space, around the brain and spinal cord.

PRODUCTION OF CSF

CSF is produced in all of the ventricles by a structure called the **choroid plexus**. This is particularly easy to see in the lateral ventricles.

REABSORPTION OF CSF

CSF is reabsorbed via a structure called **arachnoid granulations**. These cannot be seen on the specimens. Arachnoid granulations are where a part of the **arachnoid mater** (one of the three layers of meninges) protrude through the **venous sinuses**.

CLINICAL LINK: HYDROCEPHALUS

Hydrocephalus is a condition associated with excess CSF. Common presentations include headache, cognitive impairment, difficulty walking, nausea and vomiting.

There are two main types of hydrocephalus: **non-obstructive** and **obstructive**. Obstructive hydrocephalus is where there is a blockage in the ventricular system, resulting in a dilation of structures *upstream* of the blockage. For example, if a blockage is in the third ventricle, the lateral ventricles and third ventricle will be dilated, but the fourth ventricle will appear normal size. Blockage can occur due to blood or tumour.

Non-obstructive hydrocephalus is thought to be associated with dysfunction of the arachnoid granulations therefore reduced reabsorption of the CSF.

KEY TERMS

- Lateral Ventricles
- Foramen of Munro
- Third Ventricle
- Cerebral Aqueduct
- Fourth Ventricle
- Foramen of Magendie
- Foramen of Luschka
- Subarachnoid Space
- Arachnoid Granulations
- Hydrocephalus: Obstructive and non-obstructive

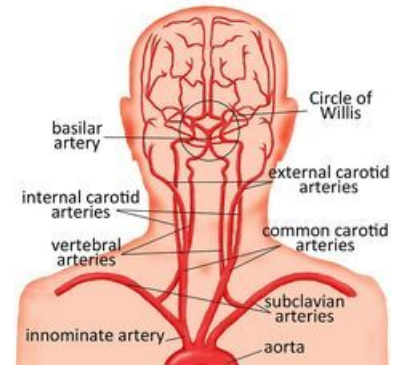
ARTERIAL SUPPLY OF THE CNS

THE BRAIN

The blood supply to the brain is derived from two sets of paired arteries:

- The **internal carotid arteries** – arising from the common carotid arteries
- The **vertebral arteries** – arising from the subclavian arteries

The internal carotids traverse the skull to emerge into the cranial vault via the **carotid canal**. It is at this point that they join the **Circle of Willis**. The central meeting point from which the vessels supplying the parenchyma of the brain arise. The vertebral arteries contribute to this circle by becoming the **basilar artery** posteriorly. All the arteries below are branches from the Circle of Willis that supply the majority of the brain.



ANTERIOR CEREBRAL ARTERIES

The **anterior cerebral arteries** are one of two pairs of arteries that arise from the internal carotid artery in the **circle of Willis**. They supply the medial surface of the frontal lobe and its upper border as well as some key central regions.

MIDDLE CEREBRAL ARTERIES

The **middle cerebral arteries** arise directly from the **internal carotids** in the **circle of Willis**. They are the second pair of arteries that do this. They supply the majority of the lateral surface of their respective hemisphere apart from a small superior part of the parietal lobe and the inferior parts of the occipital and temporal lobes.

POSTERIOR CEREBRAL ARTERIES

The **posterior cerebral arteries** arise from the basilar artery of the **circle of Willis**. They supply the majority of the occipital lobes

SPINE

The spinal cord receives its blood supply from one **anterior** and two **posterior spinal arteries** which all arise from the vertebral arteries they form a network of vessels.

CLINICAL LINK: STROKE

A stroke is defined as a clinical syndrome consisting of sudden onset of neurological symptoms due to a vascular cause lasting more than 24 hours. (<24hrs = TIA.) They can be categorised as either hemorrhagic or ischaemic. Later in the course you will be taught how to differentiate between them. For now understand that there are two clinical categories depending on the vessels affected:

- Anterior circulation
 - Anterior cerebral
 - Middle cerebral
- Posterior circulation
 - Posterior cerebral

➤ Check out this *soton brainhub rapid review of the circle of willis!*



KEY TERMS

- Internal carotid arteries
- Vertebral arteries
- Circle of Willis
- Basilar arteries
- Anterior cerebral arteries
- Middle cerebral arteries
- Posterior cerebral arteries
- Anterior and posterior spinal arteries
- Anterior circulation stroke
- Posterior circulation stroke